

Precuneus shares intrinsic functional architecture in humans and monkeys

Daniel S. Margulies^{a,b}, Justin L. Vincent^{c,d}, Clare Kelly^e, Gabriele Lohmann^b, Lucina Q. Uddin^f, Bharat B. Biswal^{g,h}, Arno Villringer^{a,b}, F. Xavier Castellanos^{e,h}, Michael P. Milham^{e,1}, and Michael Petrides^{i,1}

^aBerlin School of Mind and Brain, Humboldt Universität, 10099 Berlin, Germany; ^bMax Planck Institute for Human Cognitive and Brain Sciences, 04303 Leipzig, Germany; ^cDepartment of Psychology, Harvard University, Cambridge, MA 02138; ^dAthinoula A. Martinos Center for Biomedical Imaging, Massachusetts General Hospital, Charlestown, MA 02129; ^ePhyllis Green and Randolph Cowen Institute for Pediatric Neuroscience, New York University Child Study Center, New York, NY, 10016; ^fDepartment of Psychiatry, Stanford University School of Medicine, Stanford, CA 94304; ^gDepartment of Radiology, University of Medicine and Dentistry of New Jersey, Newark, NJ 07103; ^hNathan Kline Institute for Psychiatric Research, Orangeburg, NY 10962; and ⁱMontreal Neurological Institute, McGill University, Montreal, QC, Canada H3A 2B4

Edited by Marcus E. Raichle, Washington University School of Medicine, St. Louis, MO, and approved September 25, 2009 (received for review May 22, 2009)

Evidence from macaque monkey tracing studies suggests connectivity-based subdivisions within the precuneus, offering predictions for similar subdivisions in the human. Here we present functional connectivity analyses of this region using resting-state functional MRI data collected from both humans and macaque monkeys. Three distinct patterns of functional connectivity were demonstrated within the precuneus of both species, with each subdivision suggesting a discrete functional role: (i) the anterior precuneus, functionally connected with the superior parietal cortex, paracentral lobule, and motor cortex, suggesting a sensorimotor region; (ii) the central precuneus, functionally connected to the dorsolateral prefrontal, dorsomedial prefrontal, and multimodal lateral inferior parietal cortex, suggesting a cognitive/associative region; and (iii) the posterior precuneus, displaying functional connectivity with adjacent visual cortical regions. These functional connectivity patterns were differentiated from the more ventral networks associated with the posterior cingulate, which connected with limbic structures such as the medial temporal cortex, dorsal and ventromedial prefrontal regions, posterior lateral inferior parietal regions, and the lateral temporal cortex. Our findings are consistent with predictions from anatomical tracer studies in the monkey, and provide support that resting-state functional connectivity (RSFC) may in part reflect underlying anatomy. These subdivisions within the precuneus suggest that neuroimaging studies will benefit from treating this region as anatomically (and thus functionally) heterogeneous. Furthermore, the consistency between functional connectivity networks in monkeys and humans provides support for RSFC as a viable tool for addressing cross-species comparisons of functional neuroanatomy.

brain connectivity | functional MRI | posteromedial cortex | resting state

Compared with the lateral surface of the parietal lobe, the functional organization of the medial parietal wall has been relatively neglected. Often referred to as the precuneus, this region has been implicated in high-level cognitive functions, including episodic memory, self-related processing, and aspects of consciousness (1–3). Located in the dorsal portion of the posteromedial cortex (PMC) between the somatosensory and visual cortex, superior to the posterior cingulate and retrosplenial cortex, the precuneus is well situated to play a multimodal, integrative functional role (Fig. 1, *Top*). Its implication in many higher cognitive functions strongly suggests the presence of functional subdivisions (2, 4), although the neuroimaging literature traditionally has treated it as a homogeneous structure and typically has failed to distinguish between the precuneus and the neighboring posterior cingulate/retrosplenial cortex.

The question of how best to subdivide the human precuneus has been a source of controversy for almost a century. The cytoarchitectonic map of Brodmann (5, 6) as it appears in the atlas of Talairach and Tournoux (7) became the basis for the precuneal boundaries used in most functional neuroimaging studies. While

Brodman wrote about a gradual cytoarchitectural difference between the anterior and posterior portions of the precuneus (5, 6), his atlas demarcates it as a homogeneous entity, consisting of a medial continuation of lateral parietal area 7 (often referred to as area 7m). But other architectonic atlases (8–12) and a recent probabilistic cytoarchitectonic atlas (12, 13) suggest that more boundaries between subdivisions can be established (Fig. 1, *Bottom Right*).

Experimental anatomical investigations in monkeys have shown that cytoarchitectonic differences reflect differences in anatomical connectivity. For more than 3 decades, tracing studies in the macaque monkey have demonstrated distinct patterns of anatomical connectivity associated with specific subregions of the precuneus and posterior cingulate cortex (14–27). Specifically, experimental tract tracing studies of cortico–cortical connections in the macaque demonstrate striking anterior–posterior differentiation within the precuneus and suggest the presence of 3 distinct regions (Fig. 1, *Bottom Left*). The anteriormost part of the precuneus (PEc), along the marginal ramus of the cingulate sulcus, has strong connections with medial somatomotor regions, including supplementary motor and cingulate motor areas, as well as the superior parietal cortex (16), suggesting that it represents a sensorimotor processing zone. The central region (PGm) is richly connected to higher cognitive processing areas within the dorsolateral prefrontal cortex, the multimodal regions of the inferior parietal lobule, and the superior temporal sulcus (16, 22–25), suggesting involvement in integrative processing of cognitive information. In contrast, the posteriormost portion (PO), which runs along the dorsal parieto-occipital sulcus, has strong connections with prestriate areas hidden within the parieto-occipital fissure and the cuneus (27), areas related to visual information processing. Finally, the precuneus as a whole is differentiated from the posterior cingulate cortex, which has strong anatomical connections to limbic regions [[supporting information \(SI\) Text, i](#)], including the ventromedial prefrontal cortex and the limbic medial temporal region (14, 15, 17, 28). Thus, the monkey anatomical literature provides the basis for specific hypotheses about functional subdivisions and boundaries of the human precuneal cortex.

Author contributions: D.S.M., C.K., L.Q.U., B.B.B., F.X.C., M.P.M., and M.P. designed research; D.S.M., J.L.V., C.K., and L.Q.U. performed research; D.S.M., J.L.V., C.K., G.L., B.B.B., and M.P.M. contributed new reagents/analytic tools; D.S.M., J.L.V., G.L., and M.P. analyzed data; and D.S.M., C.K., A.V., F.X.C., M.P.M., and M.P. wrote the paper.

The authors declare no conflict of interest.

This article is a PNAS Direct Submission.

Freely available online through the PNAS open access option.

Data deposition: Human and monkey data are available at www.brainscape.org.

¹To whom correspondence may be addressed. E-mail: michael.milham@nyumc.org or michael.petrides@mcgill.ca.

This article contains supporting information online at www.pnas.org/cgi/content/full/0905314106/DCSupplemental.

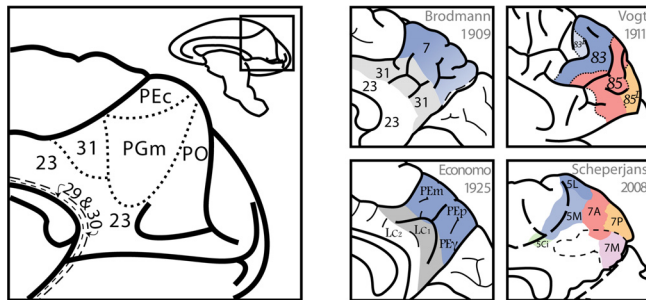
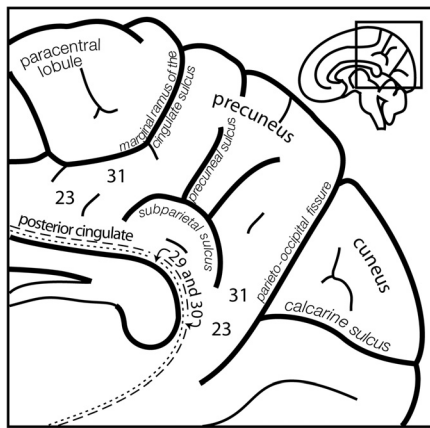


Fig. 1. (Top) Schematic diagram illustrating the human PMC including the precuneus, the posterior cingulate cortex (area 23), the retrosplenial cortex in the posterior callosal sulcus (areas 29 and 30), and the transitional zone (area 31) that separates the precuneus from the cingulate cortex. The precuneus is located between the marginal ramus of the cingulate sulcus and the parieto-occipital fissure. (Bottom Left) The macaque monkey PMC with divisions primarily delineated from anatomical connectivity studies. (Bottom Right) Architectonic anatomical maps and their proposed subdivisions of the human precuneus.

Functional MRI (fMRI) resting-state functional connectivity (RSFC) analysis (29) provides a unique means of mapping functional networks within complex brain regions *in vivo* (30–33). The aim of the present study was to determine whether the patterns of anatomical connectivity in tract tracing studies of monkey PMC are preserved in RSFC data obtained *in vivo*, and whether they also reflect patterns observed in the human brain. Consequently, we conducted the same RSFC analyses in both monkeys (34) and humans to test anatomical tracing predictions without interspecies confounds and also to provide a methodologically similar basis for cross-species comparisons with RSFC analysis in humans.* Twenty-one seed regions-of-interest (ROIs) throughout the PMC were manually selected with reference to individual sulcal patterns (Fig. 2) for 8 macaque monkeys and 40 human participants; see *SI Materials and Methods* for a detailed description of seed placement. In both data sets, voxelwise RSFC analyses for each seed region were performed as described previously (30, 31). Seed regions exhibiting distinct patterns of RSFC were identified by visual inspection and then subjected to direct whole-brain voxelwise comparison with one another to ensure that differences were statistically significant. In addition, spectral clustering analyses were applied to delineate boundaries and validate subdivisions, independent of observer bias.

Results

Consistent with predictions from experimental anatomical studies in the macaque monkey, 3 distinct RSFC patterns within the

*While the human data were acquired during the “resting state,” the monkeys were scanned while under anesthesia. However, for the sake of convention, both are addressed here as “resting state.”

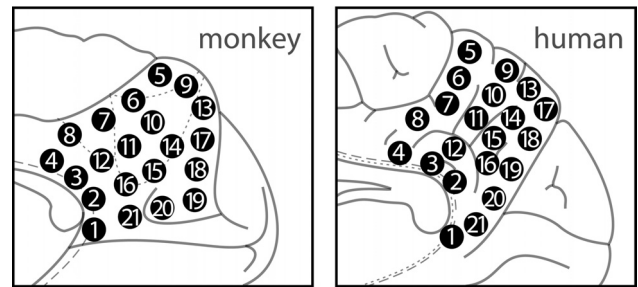


Fig. 2. Placement of 21 seed regions in monkeys (Left) and humans (Right). Descriptions of the seeds in relation to sulcal landmarks and average coordinates in the MNI152 space are provided in *SI Materials and Methods* and *Table S1*.

precuneus were seen in both monkeys and humans: anterior sensorimotor-related, central multimodal/cognitive-related, and posterior visually-related. These 3 functional subdivisions were differentiable across the anterior-posterior extent of the precuneus. Furthermore, the precuneus as a whole was differentiated from the more ventral posterior cingulate/retrosplenial region, which exhibited extensive RSFC with limbic regions (Fig. 3).

These patterns of connectivity are described below in detail. Voxelwise results in humans and monkeys for each seed are given in *SI Appendix*, Figs. S1–S3 and *Table S1* for specific cluster results related to each seed region in humans.

Sensorimotor Anterior Precuneal Region. An anterior dorsal zone along the marginal ramus of the cingulate sulcus (seeds 5 and 6) exhibited RSFC with sensorimotor-related areas of the medial surface of the brain. Strong RSFC was observed with the adjacent cortex on the paracentral lobule (the medial extension of the central sensorimotor cortex), medial premotor area 6 (supplementary motor area), and the adjacent cingulate motor cortex. On the lateral surface of the brain, there was RSFC with the primary motor cortex on the precentral gyrus, premotor area 6, somatosensory area 2 on the postcentral gyrus (see Fig. 3, Row 1, showing seed 6), and, unique to seed 6, with the secondary somatosensory cortex in the parietal operculum and insula. In the human brain, there was additional RSFC with the caudalmost part of the parahippocampal region and the superior temporal gyrus. The lack of monkey RSFC to the temporoparietal cortex, which is described by anatomical tracing (16), is one example of the differences found between anatomical and RSFC mapping.

In general, however, the RSFC observations were remarkably consistent with those of anatomical tracing studies of the corresponding PEc area in monkeys, in that the anatomical connectivity also remained restricted to the somatomotor-associated caudal portion of the superior parietal lobule (case 1 in ref. 23 and case 1 in ref. 22) and did not cross the intraparietal sulcus to involve multisensory inferior parietal lobule (Fig. 3, row 1). Moreover, consistent with experimental tracing studies (cases 2, 7, and 8 in ref. 16), RSFC did not extend more anteriorly than the premotor cortex.

The ventral limit of this somatomotor-related zone is difficult to establish in living animals. The ventralmost portion (seed 7) of this region, particularly in humans, showed RSFC with the anterior part of the cuneus next to the parieto-occipital fissure and anterior calcarine sulcus, suggesting the presence of a transitional zone (perhaps related to area 31). This observation is not without precedent in the anatomical tracing literature; Parvizi et al. (15) observed connectivity of this area in monkeys with prostriate areas located adjacent and anterior to the calcarine fissure.

Cognitive/Associative Central Precuneal Region. The region in the central precuneus adjacent to the precuneal sulcus (in humans, seeds 14 and 15; in monkeys, seeds 10, 14, and 15) exhibited RSFC with the multisensory posterior inferior parietal lobule (especially




Fig. 3. Four seed regions were selected that exemplified the markedly different patterns described in *Results*. (The results of voxelwise analyses for all seeds are given in *SI Appendix*, Figs. S1–S3, and statistical results for human seeds are given in *Table S1*.) The 4 specific seed regions presented here (left column) have been classified by the functional roles implied by their functional connectivity patterns, and the results are compared with anatomical connectivity findings from macaque monkeys after injection of tracers within a location comparable to the respective seed region.

the angular gyrus in the human brain) and, in monkeys, the homologous region that involves cortex surrounding the caudal superior temporal sulcus. There was also significant RSFC for human seed 14 and monkey seeds 14 and 15 with the dorsolateral prefrontal cortex (area 10, area 46 within the intermediate frontal sulcus in the human brain, and area 8 on the middle frontal gyrus), but no RSFC was present for any of these seeds with premotor, motor, or somatosensory areas. (The consistency of this subdivision can be seen in the contrasts in *SI Appendix*, Figs. S4 and S5).

The transition from sensorimotor-related superior parietal RSFC to cognitive-related inferior parietal RSFC (Fig. 3, rows 1 and 2) is consistent with the macaque tracing literature. The superior parietal cortex is anatomically connected with somatomotor-related areas, while inferior parietal areas are connected to the prefrontal cortex (compare case 1 with cases 15 and 16 in ref. 24). In line with these observations, RSFC of the central precuneal region in monkeys was found with dorsolateral prefrontal cortex, predominantly dorsal to the sulcus principalis. Similarly, anatomical

connectivity to dorsal prefrontal areas anterior to the arcuate sulcus was observed only for inferior parietal areas, the retrosplenial cortex, and the ventral PGM (central precuneal region), but not with areas along the marginal ramus or dorsal precuneus (cases 2 and 6 in ref. 35). Both monkeys and humans also exhibited RSFC with dorsal portions of the medial prefrontal cortex (see Fig. 3, *SI Appendix*, Figs. S1–S3, and *Table S1* for seeds 13 and 14), but much less than that exhibited by the ventrally adjacent posterior cingulate cortex (see the contrasts between the cognitive and limbic zones in *SI Appendix*, Fig. S4 and *Table S5*).

The cognitive functional role that we ascribe to this central precuneal region, designated PGM in the monkey (25), is suggested by its strong RSFC with the multisensory area PG of the posterior inferior parietal cortex and adjacent caudal superior temporal sulcus, which in the human brain is the angular gyrus (case 8 in ref. 25), and with dorsal prefrontal cortex (case 9 in ref. 24). These dorsal prefrontal areas have been implicated in higher-order executive processing, such as monitoring of information in working

memory and action planning (36). Furthermore, the RSFC found with dorsomedial prefrontal areas 8B and portions of medial area 32 also is consistent with the tracing literature (case 2 in ref. 23; case 15 in ref. 24).

Visual Posterior Precuneal Region. The zone along the dorsal portion of the parieto-occipital fissure (seeds 17–19) (*SI Text, ii*) shows strong RSFC with the visually related cortex of the cuneus and lateral prestriate region. In humans, the ventral portion of this region (seed 17) exhibited RSFC with the posterior fusiform gyrus. More ventrally (seed 18), there was RSFC with the retrosplenial and posterior cingulate cortex, suggesting the presence of a transition from the parieto-occipital to parieto-limbic cortex.

Limbic Functional Connectivity Differentiates the Precuneus from Posterior Cingulate/Retrosplenial Region. The ventral PMC (seeds 1–4, 8, 12, 16, 20, and 21), comprising the cingulate gyrus and the adjacent retrosplenial cortex hidden within the callosal sulcus around the splenium, demonstrated RSFC with limbic regions, such as the anterior cingulate, paracingulate, and medial prefrontal cortex, as well as the dorsolateral prefrontal cortex and inferior parietal lobule, extending in humans as far as the ventral part of the parieto-occipital fissure (Fig. 3, row 1; *SI Appendix*, Figs. S1 and S2, and S3; seeds 19 and 20). The anatomical connectivity of this ventral region of the PMC is distinguished from that of the precuneus here and in the macaque monkey tracing studies by (*i*) its strong connectivity with the ventromedial prefrontal cortex (ref. 19; case 1 in ref. 16) and (*ii*) its connectivity in humans with the limbic medial temporal region, including the parahippocampal gyrus and hippocampus (cases 1, 3, and 5 in ref. 37; ref. 38).

Within the posterior cingulate region, clear differences were also noted between anterior and posterior portions (Fig. 4 and *SI Appendix*, Figs. S1 and S6C). In humans, while posterior area 23 exhibited RSFC that was primarily localized to proximal posterior regions, the anterior section of area 23 (seeds 4 and 12), as well as all of what may be considered transitional area 31 (*SI Text, iii*) (seed 8), exhibited widespread RSFC with the dorsal medial frontal cortex. This pattern of dorsal medial prefrontal RSFC was completely absent for areas above the subparietal sulcus (e.g., compare human seeds 12 and 14 in *SI Appendix*, Figs. S1–S3). In monkeys, retrosplenial cortex (seeds 2 and 3) also exhibited similar dorsal medial prefrontal RSFC. These observations also are consistent with the tract tracing literature, in which anatomical connectivity between areas 23/31 and area 32 in the dorsal medial prefrontal cortex remained rostral to the genu of the corpus callosum (case 3 in ref. 16).

Clustering Analysis of Seed Regions. Spectral clustering of the time series from the seed regions within the PMC (*SI Appendix*, Fig. S6) revealed subdivisions in humans and monkeys that were consistent with the subdivisions observed through visually parsing voxelwise RSFC analyses. In addition, the posterior cingulate cortex also was divided into a dorsal region and a ventral region, reflecting previously noted functional divisions that are beyond the scope of the present study (39). The 5 cluster solutions in humans and monkeys, which displayed 3 subdivisions in the dorsal PMC, demonstrated RSFC from averaged seeds within each cluster that generally paralleled the distribution of patterns observed in the individual seed regions (*SI Appendix*, Fig. S6C).

Discussion

Most functional analyses of the PMC fail to distinguish subdivisions within the precuneus, presumably due to the dominant influence of Brodmann's atlas on the functional neuroimaging literature (6, 7). In addition, the PMC often is not distinguished from the posterior cingulate cortex. By applying RSFC analyses to resting-state fMRI data acquired from both humans and macaque monkeys, we observed clear distinctions between the patterns of functional

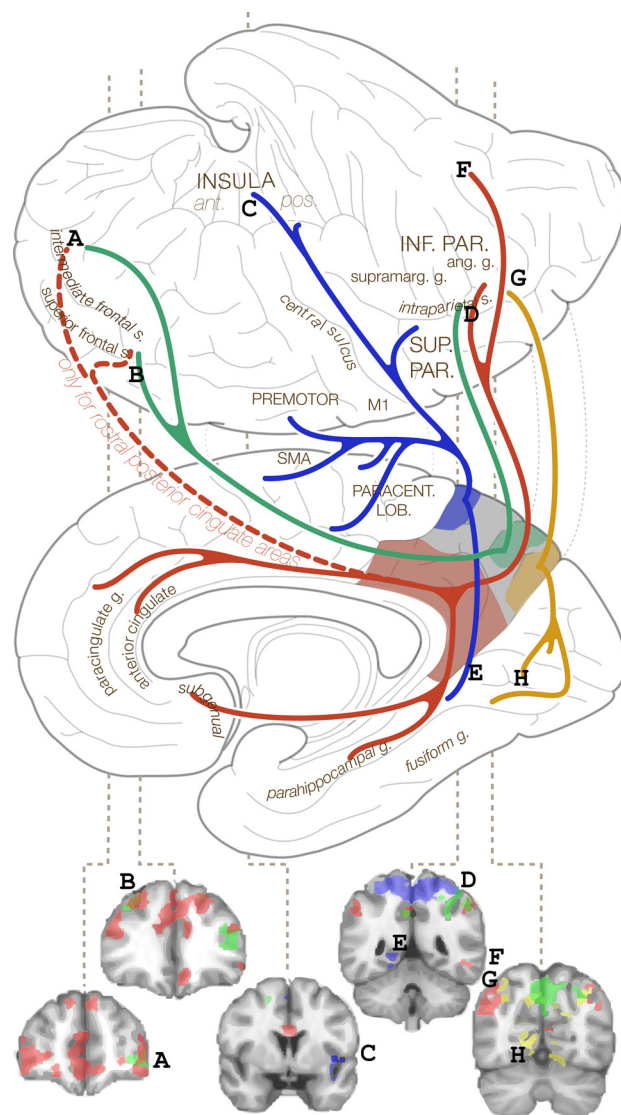


Fig. 4. Summary of functional connectivity patterns emerging from the 3 precuneus subdivisions and the posterior cingulate. At the bottom are select coronal slices, designated A–H to clarify characteristic delineations between PMC subdivisions.

connectivity both within and between these regions, which are supported by classical and recent anatomical studies. Three distinct and novel functional connectivity patterns were discerned within the precuneus that suggest anterior-to-posterior anatomical/functional subdivisions: (*i*) an anterior zone along the marginal ramus of the cingulate sulcus that exhibits functional connectivity with sensorimotor regions; (*ii*) a central cognitive/multimodal zone that exhibits functional connectivity with the posterior part of the inferior parietal lobule and the adjacent superior temporal sulcus (in the human brain the morphological structure known as the angular gyrus, corresponding to area PG and caudal superior temporal sulcus in the monkey) and dorsolateral prefrontal cortex; and (*iii*) a posterior zone along the parieto-occipital fissure that exhibits functional connectivity with the visual prestriate cortex in the cuneus and the dorsal lateral occipital region (see Fig. 4 for a summary of findings in humans). Despite substantial differences in the methods of data acquisition in monkeys and humans (see *SI Text, iv*), the subdivision-specific functional connectivity patterns were remarkably consistent between species and with predictions from previous tract tracing anatomical studies in the monkey. The

results suggest that future functional neuroimaging studies should consider the substantial heterogeneity of the PMC.

Comparison of Anatomical and Functional Connectivity. While RSFC approaches provide intricate statistical maps that appear to reveal underlying neuronal circuitry, the anatomical foundations of the patterns revealed by this approach remain uncertain. The presence of functional connectivity between left and right macaque area V1 suggests that BOLD correlations do not necessarily reflect monosynaptic anatomical connectivity (34). Despite obvious differences in scale and complexity between human and macaque brains and differences in data collection between the 2 species, the RSFC relationships that we observed *in vivo* were largely consistent with anatomical tracing studies in the monkey, although some differences were also noted, suggesting that this emerging technique does reflect aspects of underlying anatomical connectivity. While several recent comparisons of structural and functional connectivity support a relationship between these measures (40–42), multiple factors may influence patterns of RSFC (43, 44), and, as we have observed, the relationship with anatomical connectivity is not a 1:1 correspondence.

Relevance to Human Functional Literature. The Brodmann map (5, 6) used in modern functional neuroimaging (7) identifies the precuneus as a unitary functional entity, termed medial area 7. A new probabilistic atlas of the superior parietal cortex (including the precuneus), based on cytoarchitectonic divisions across several brains, offers a more reliable map of subdivisions in this region (12, 13) (see also Fig. 1, *Bottom Right*). The lack of consensus in differentiating the precuneus from the posterior cingulate/retrosplenial cortex and the realization that the precuneus itself is not a homogeneous cortical region may have resulted in a misattribution of function. Consequently, some precuneus distinctions have been proposed, and more are likely to follow. In a review of functional activation studies of the precuneus, Cavanna and Trimble (2) distinguished an anterior region involved in self-centered mental imagery strategies from a posterior region associated with successful retrieval of episodic memory, and further attributed a subdivision of the precuneus to the processing of visuospatial imagery.

Relevance to Human Functional Connectivity Literature. The functional connectivity between the precuneus and primary motor cortex, which we found to be specific to its anterior portion, was reported previously (see figure 3b in ref. 29 and figure 4b in ref. 45). The region in the central precuneus in and around the posterior precuneal sulcus (seed 14), which we functionally describe as a cognitive/associative network, may relate to earlier reports of a frontoparietal control system (46–49). Aspects of this network also were identified in the rostral posterior cingulate (seed 4), which is consistent with previous findings describing this network as specifically linked to both the rostral posterior cingulate and the central precuneus (32, 47, 49). With regard to our finding of functional connectivity between the posterior precuneus and visual cortex, it is interesting to note the report of a sparse set of “bridge” connections between these modules in the human brain (50).

The Precuneus and the Default-Mode Network. The inclusion of the PMC in the “default-mode” network has become a truism. Indeed, this broad region has been suggested to be a “core node” or “hub” of the default-mode network (40, 51). However, recent work with high-resolution RSFC data has suggested that in fact the precuneus is not a component of the default-mode network, which instead has a dorsal terminus near the subparietal sulcus (52). Our findings support this view, as we observed parahippocampal and ventral medial prefrontal functional connectivity, which is characteristic of the default-mode network (33, 46, 52–56), exclusively with the more ventral posterior cingulate gyrus (including human seeds 4, 12, 16,

20, and 21). Interestingly, the dorsal posterior cingulate seeds (12 and 16) were less correlated with the medial temporal lobe and more correlated with the lateral temporal cortex, which is reminiscent of the functional connectivity of perirhinal cortex, although the perirhinal cortex was not identified in the present analyses (33). The most ventral posterior cingulate seeds (including seeds 20 and 21) were correlated with a system of regions closely corresponding to the hippocampal and parahippocampal network previously identified as being responsive to recollection (33, 49, 55). Of note, the rostral posterior cingulate (seed 4) was correlated with 2 distinct networks, including the frontoparietal control system as well as aspects of the hippocampal cortical memory system, including the ventral prefrontal cortex and parahippocampus (*SI Appendix*, Figs. S1 and S2). This is consistent with a recent report of a region in rostral posterior cingulate that appears to be transitional, correlating with both the anterior prefrontal cortex and hippocampal formation (49). Nonetheless, the divergent findings across studies with respect to dorsal–ventral boundaries of the default-mode network may be sensitive to preprocessing steps (e.g., smoothing kernel size) and statistical methods. Thus, our findings in this regard should be treated as preliminary.

Limitations. The scope of this paper is restricted to addressing subdivisions based on cortico–cortical connections. Although sub-cortical and cerebellar connectivity also may be relevant, we focused on cortico–cortical relations because the available extensive monkey anatomical literature regarding the PMC allows for the generation of specific hypotheses regarding such connectivity. It should be noted that, although we attempted to limit variability across subjects (e.g., through selection of seed regions from individual anatomy), the statistical analyses were still carried out in standard stereotaxic space. In an attempt to balance the maintenance of individual specificity with the need for group-level analyses, spatial smoothing was conducted with a reduced 4.5-mm Gaussian kernel. This smaller smoothing kernel also may have facilitated more specific localization, especially with respect to precuneus/posterior cingulate subdivision.

Conclusion

While the resurgence of interest in the precuneus has generated novel research questions regarding high-level cognition (1–3), it would be erroneous to overattribute functional roles in the absence of clear evidence. The search for common denominators of these functions must be accompanied by efforts to delineate functional subdivisions based on anatomical evidence. We suggest that a more complete understanding of the potential involvement of the precuneus in a diverse array of clinical and psychiatric conditions, as well as a wide range of cognitive tasks, may benefit from the consideration of functional boundaries within the precuneus and also between the precuneus and posterior cingulate cortex. We propose that the subdivisions based on precuneal functional connectivity patterns observed in the human brain, which are related to tracing studies in the macaque monkey, can serve as initial markers for further investigation.

We have shown that the precuneus and other areas within the PMC comprise a series of related but discrete regions that participate in distinct functional networks. This differentiation is especially important considering the rise of interest in the default-mode network, the posterior component of which is typically referred to as a single homogenous region, the “posterior cingulate/precuneus.” The clear differentiation of the precuneus into 3 functionally relevant anterior–posterior subdivisions merits further attention in the evaluation of activation/connectivity loci within the region. Further work is needed to understand how the complexity of precuneus, and its interactions in several large-scale networks that have been preserved across species, relates to high-level processing in both humans and nonhuman primates.

Methods

Data Acquisition. The human data reported here include 40 right-handed native English-speaking participants (20 females; mean age, 28.6 ± 7.6 years) from previously published studies (30, 31). The monkey data include 8 anesthetized monkeys (6 *Macaca fascicularis* and 2 *M. Mulatta*) published previously (34) and now freely available online (<http://www.brainscape.org/>). See *SI Materials and Methods* for acquisition details.

Functional Connectivity Analysis. Preprocessing, seed selection, and time series extraction. After individual spherical seed regions were created for each individual, human data were put through similar processing paths as described previously (30, 31) (see *SI Materials and Methods* for more information). The monkey preprocessing (smoothing/filtering) was different (see ref. 34 for details). Seeds were selected on an individual basis with respect to sulcal patterns after the anatomical scans had been registered to standard space (see *SI Materials and Methods* for details of seed selection). Seed placement ensured that all seeds were separated by at least 6 mm. Table S1 shows the averaged coordinates of each seed point across human individuals; also see Fig. 2 for general location with respect to sulcal patterns in both humans and monkeys. Spherical ROIs (humans, 3 mm radius; monkeys, 1.5 mm radius) were generated around each seed coordinate. Time series were extracted from averaged voxels within each ROI mask.

Statistical analyses. For each individual seed, voxelwise multiple regression analyses (using the GLM implemented in FSL's FEAT) were performed, with the seed time series and 9 nuisance covariates (global signal, white matter and cerebrospinal fluid signals, and 6 motion parameters) as predictors. Individual seed time series were orthogonalized with respect to the nuisance covariates. Comparisons of 4 selected seed regions also were tested by contrasting on an individual level using a fixed-effects model (*SI Appendix*, Figs. S2 and S3). Group-level analyses were carried out using a mixed-effects model (FLAME). Corrections for multiple comparisons were carried out at the cluster level using Gaussian random field theory (minimum voxel z-score, > 2.3 ; cluster significance, $P < .05$, corrected). Although detected, negative correlations are beyond the focus of this study and are not discussed here.

ACKNOWLEDGMENTS. We thank David Stark and Amelie Diester for assistance with manual seed selection and Will Brady for graphic design consultation. This work was supported by the Stavros S. Niarchos Foundation, the National Institute on Drug Abuse (Grant DA016979), the Berlin School of Mind and Brain, and the Canadian Institutes of Health Research (Grant MOP-14620). The monkey data were originally funded by the National Institute of Neurological Disorders and Stroke (Grant NS 06833) and discretionary research funds from the Mallinckrodt Institute of Radiology at Washington University, and have been made publicly available at www.brainscape.org.

- Vogt BA, Laureys S (2005) Posterior cingulate, precuneal and retrosplenial cortices: Cytology and components of the neural network correlates of consciousness. *Prog Brain Res* 150:205–217.
- Cavanna AE, Trimble MR (2006) The precuneus: A review of its functional anatomy and behavioural correlates. *Brain* 129:564–583.
- Cavanna AE (2007) The precuneus and consciousness. *CNS Spectr* 12:545–552.
- Nickel J, Seitz RJ (2005) Functional clusters in the human parietal cortex as revealed by an observer-independent meta-analysis of functional activation studies. *Anat Embryol (Berl)* 210:463–472.
- Brodman K (1909) *The Principles of Comparative Localization of the Cerebral Cortex Based on Cytoarchitectonics* (Translated from German) (Johann Ambrosius Barth, Leipzig).
- Brodman K, Gary LJ (2006) *Brodman's Localization in the Cerebral Cortex: The Principles of Comparative Localization in the Cerebral Cortex Based on Cytoarchitectonics* (Springer, New York).
- Talairach J, Tournoux P (1988) *Co-Planar Stereotaxic Atlas of the Human Brain* (Thieme, Stuttgart).
- Economo C, Koskinas GN (1925) *The Cytoarchitectonics of the Cerebral Cortex of the Human Adult* (Translated from German) (Julius Springer, Vienna-Berlin).
- Vogt O (1911) *The myeloarchitectonics of parietal isocortex* (Translated from German). *J Psychol Neurol* 18:379–396.
- Sarkisov SA, Filimonoff IN, Preobrashenskaya NS (1955) *Cytoarchitecture of the Human Cortex Cerebri* (translated from Russian) (Medgiz, Moscow).
- Smith EG (1907) A new topographical survey of the human cerebral cortex, being an account of the distribution of the anatomically distinct cortical areas and their relationship to the cerebral sulci. *J Anat Physiol* 41:237–254.
- Scheperjans F, et al. (2008) Observer-independent cytoarchitectonic mapping of the human superior parietal cortex. *Cereb Cortex* 18:846–867.
- Scheperjans F, et al. (2008) Probabilistic maps, morphometry, and variability of cytoarchitectonic areas in the human superior parietal cortex. *Cereb Cortex* 18:2141–2157.
- Kobayashi Y, Amaral DG (2007) Macaque monkey retrosplenial cortex, III: Cortical efferents. *J Comp Neurol* 502:810–833.
- Parvizi J, Van Hoesen GW, Buckwalter J, Damasio A (2006) Neural connections of the posteromedial cortex in the macaque. *Proc Natl Acad Sci USA* 103:1563–1568.
- Morecraft RJ, Cipolloni PB, Stilwell-Morecraft KS, Gedney MT, Pandya DN (2004) Cytoarchitecture and cortical connections of the posterior cingulate and adjacent somatosensory fields in the rhesus monkey. *J Comp Neurol* 469:37–69.
- Kobayashi Y, Amaral DG (2003) Macaque monkey retrosplenial cortex, II: Cortical afferents. *J Comp Neurol* 466:48–79.
- Leichnetz GR (2001) Connections of the medial posterior parietal cortex (area 7m) in the monkey. *Anat Rec* 263:215–236.
- Morris R, Petrides M, Pandya DN (1999) Architecture and connections of retrosplenial area 30 in the rhesus monkey (*Macaca mulatta*). *Eur J Neurosci* 11:2506–2518.
- Morris R, Pandya DN, Petrides M (1999) Fiber system linking the mid-dorsolateral frontal cortex with the retrosplenial/presubicular region in the rhesus monkey. *J Comp Neurol* 407:183–192.
- Morecraft RJ, Van Hoesen GW (1998) Convergence of limbic input to the cingulate motor cortex in the rhesus monkey. *Brain Res Bull* 45:209–232.
- Cavada C, Goldman-Rakic PS (1989) Posterior parietal cortex in rhesus monkey, I: Parcellation of areas based on distinctive limbic and sensory corticocortical connections. *J Comp Neurol* 287:393–421.
- Cavada C, Goldman-Rakic PS (1989) Posterior parietal cortex in rhesus monkey, II: Evidence for segregated corticocortical networks linking sensory and limbic areas with the frontal lobe. *J Comp Neurol* 287:422–445.
- Petrides M, Pandya DN (1984) Projections to the frontal cortex from the posterior parietal region in the rhesus monkey. *J Comp Neurol* 228:105–116.
- Pandya DN, Seltzer B (1982) Intrinsic connections and architectonics of posterior parietal cortex in the rhesus monkey. *J Comp Neurol* 204:196–210.
- Buckwalter JA, Parvizi J, Morecraft RJ, van Hoesen GW (2008) Thalamic projections to the posteromedial cortex in the macaque. *J Comp Neurol* 507:1709–1733.
- Colby CL, Gattass R, Olson CR, Gross CG (1988) Topographical organization of cortical afferents to extrastriate visual area PO in the macaque: A dual tracer study. *J Comp Neurol* 269:392–413.
- Saleem KS, Kondo H, Price JL (2008) Complementary circuits connecting the orbital and medial prefrontal networks with the temporal, insular, and opercular cortex in the macaque monkey. *J Comp Neurol* 506:659–693.
- Biswal B, Yetkin FZ, Haughton VM, Hyde JS (1995) Functional connectivity in the motor cortex of resting human brain using echo-planar MRI. *Magn Reson Med* 34:537–541.
- Margulies DS, et al. (2007) Mapping the functional connectivity of anterior cingulate cortex. *Neuroimage* 37:579–588.
- Di Martino A, et al. (2008) Functional connectivity of human striatum: A resting-state fMRI study. *Cereb Cortex* 12:2735–2747.
- Cohen AL, et al. (2008) Defining functional areas in individual human brains using resting functional connectivity MRI. *Neuroimage* 41:45–57.
- Kahn I, Andrews-Hanna JR, Vincent JL, Snyder AZ, Buckner RL (2008) Distinct cortical anatomy linked to subregions of the medial temporal lobe revealed by intrinsic functional connectivity. *J Neurophysiol* 100:129–139.
- Vincent JL, et al. (2007) Intrinsic functional architecture in the anaesthetized monkey brain. *Nature* 447:83–86.
- Petrides M, Pandya DN (1999) Dorsolateral prefrontal cortex: Comparative cytoarchitectonic analysis in the human and the macaque brain and corticocortical connection patterns. *Eur J Neurosci* 11:1011–1036.
- Petrides M (2005) Lateral prefrontal cortex: Architectonic and functional organization. *Philos Trans R Soc Lond B Biol Sci* 360:781–795.
- Blatt GJ, Pandya DN, Rosene DL (2003) Parcellation of cortical afferents to three distinct sectors in the parahippocampal gyrus of the rhesus monkey: An anatomical and neurophysiological study. *J Comp Neurol* 466:161–179.
- Suzuki WA, Amaral DG (1994) Perirhinal and parahippocampal cortices of the macaque monkey: Cortical afferents. *J Comp Neurol* 350:497–533.
- Vogt BA, Vogt L, Laureys S (2006) Cytology and functionally correlated circuits of human posterior cingulate areas. *Neuroimage* 29:452–466.
- Hagmann P, et al. (2008) Mapping the structural core of human cerebral cortex. *PLoS Biol* 6:e159.
- Honey CJ, et al. (2009) Predicting human resting-state functional connectivity from structural connectivity. *Proc Natl Acad Sci USA* 106:2035–2040.
- Skudlarski P, et al. (2008) Measuring brain connectivity: Diffusion tensor imaging validates resting-state temporal correlations. *Neuroimage* 43:554–561.
- Ghosh A, Rho Y, McIntosh AR, Kötter R, Jirsa VK (2008) Noise during rest enables the exploration of the brain's dynamic repertoire. *PLoS Comput Biol* 4:e1000196.
- Harrison BJ, et al. (2008) Modulation of brain resting-state networks by sad mood induction. *PLoS ONE* 3:e1794.
- Fox MD, Snyder AZ, Vincent JL, Raichle ME (2007) Intrinsic fluctuations within cortical systems account for intertrial variability in human behavior. *Neuron* 56:171–184.
- Damoiseaux JS, et al. (2006) Consistent resting-state networks across healthy subjects. *Proc Natl Acad Sci USA* 103:13848–13853.
- Dosenbach NU, et al. (2007) Distinct brain networks for adaptive and stable task control in humans. *Proc Natl Acad Sci USA* 104:11073–11078.
- Seeley WW, et al. (2007) Dissociable intrinsic connectivity networks for salience processing and executive control. *J Neurosci* 27:2349–2356.
- Vincent JL, Kahn I, Snyder AZ, Raichle ME, Buckner RL (2008) Evidence for a frontoparietal control system revealed by intrinsic functional connectivity. *J Neurophysiol* 100:3328–3342.
- He Y, et al. (2009) Uncovering intrinsic modular organization of spontaneous brain activity in humans. *PLoS ONE* 4:e5226.
- Fransson P, Marrelec G (2008) The precuneus/posterior cingulate cortex plays a pivotal role in the default mode network: Evidence from a partial correlation network analysis. *Neuroimage* 42:1178–1184.
- Buckner RL, Andrews-Hanna JR, Schacter DL (2008) The brain's default network: Anatomy, function, and relevance to disease. *Ann NY Acad Sci* 1124:1–38.
- Greicius MD, Krasnow B, Reiss AL, Menon V (2003) Functional connectivity in the resting brain: A network analysis of the default mode hypothesis. *Proc Natl Acad Sci USA* 100:253–258.
- Greicius MD, Menon V (2004) Default-mode activity during a passive sensory task: Uncoupled from deactivation but impacting activation. *J Cogn Neurosci* 16:1484–1492.
- Vincent JL, et al. (2006) Coherent spontaneous activity identifies a hippocampal-parietal memory network. *J Neurophysiol* 96:3517–3531.
- Fox MD, et al. (2005) The human brain is intrinsically organized into dynamic, anticorrelated functional networks. *Proc Natl Acad Sci USA* 102:9673–9678.